

症例1 甲状腺

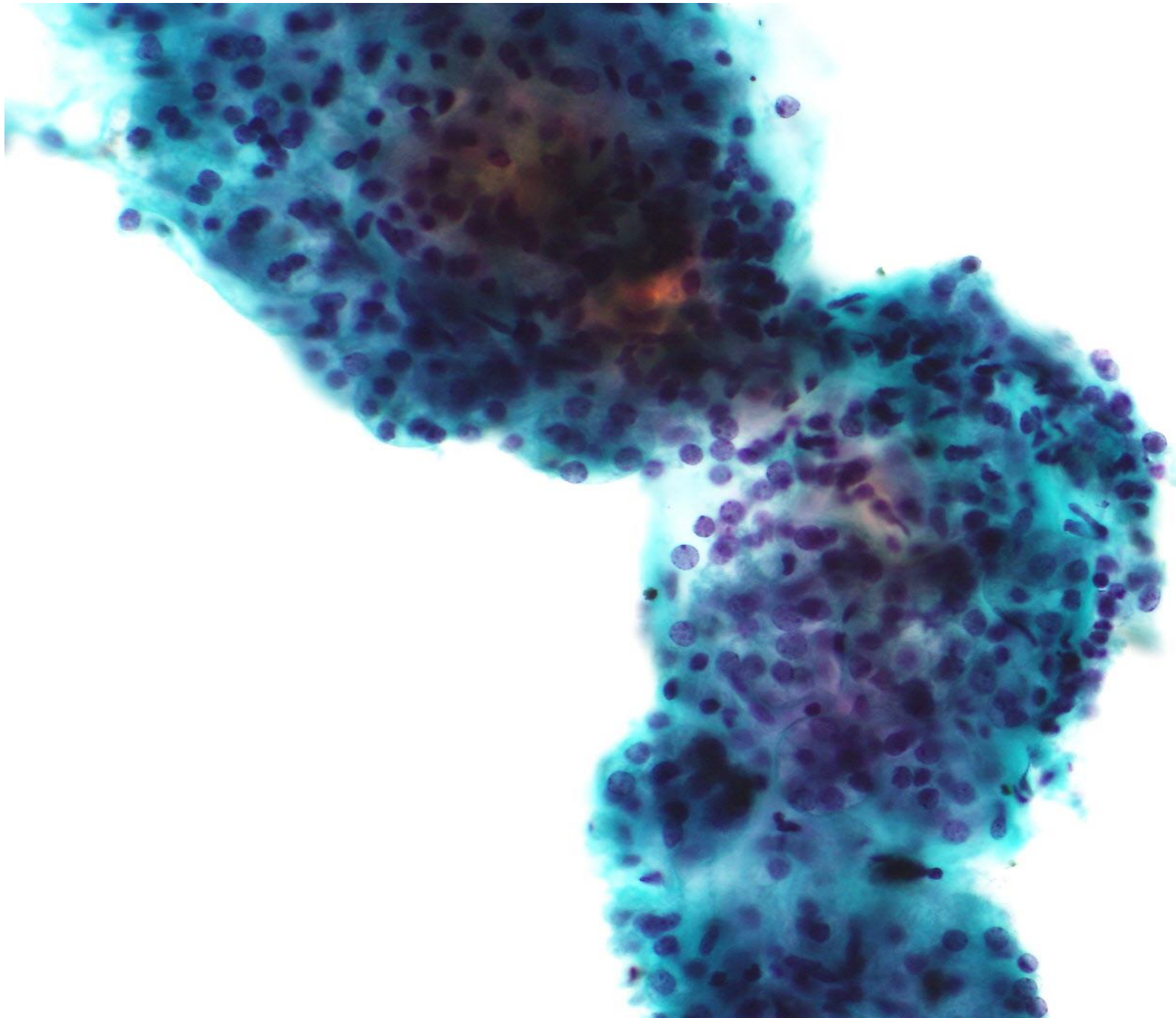
20代 女性

甲状腺：右葉結節

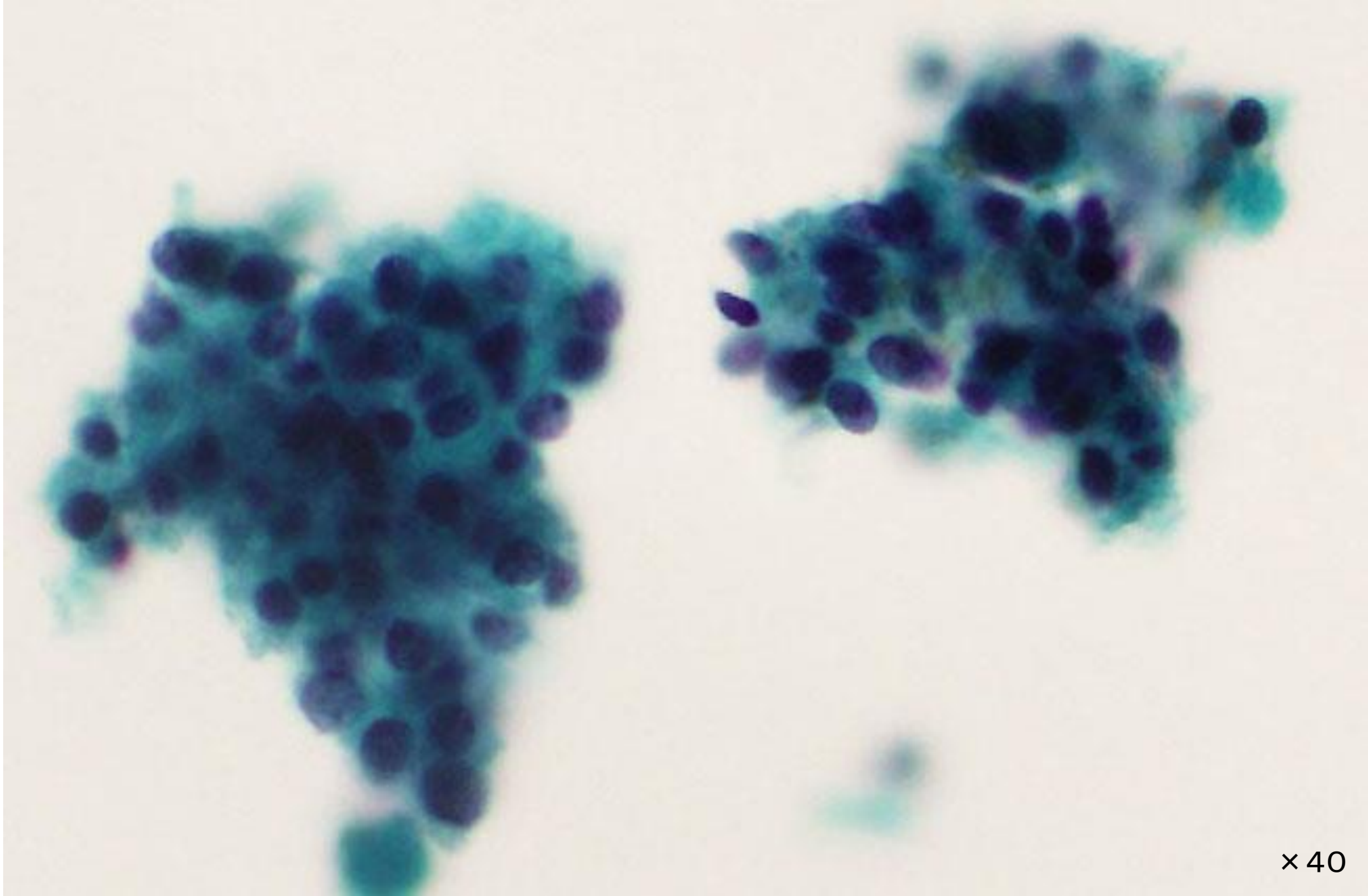
健診にて発覚し、帝京大学病院より紹介受診

Tg:61

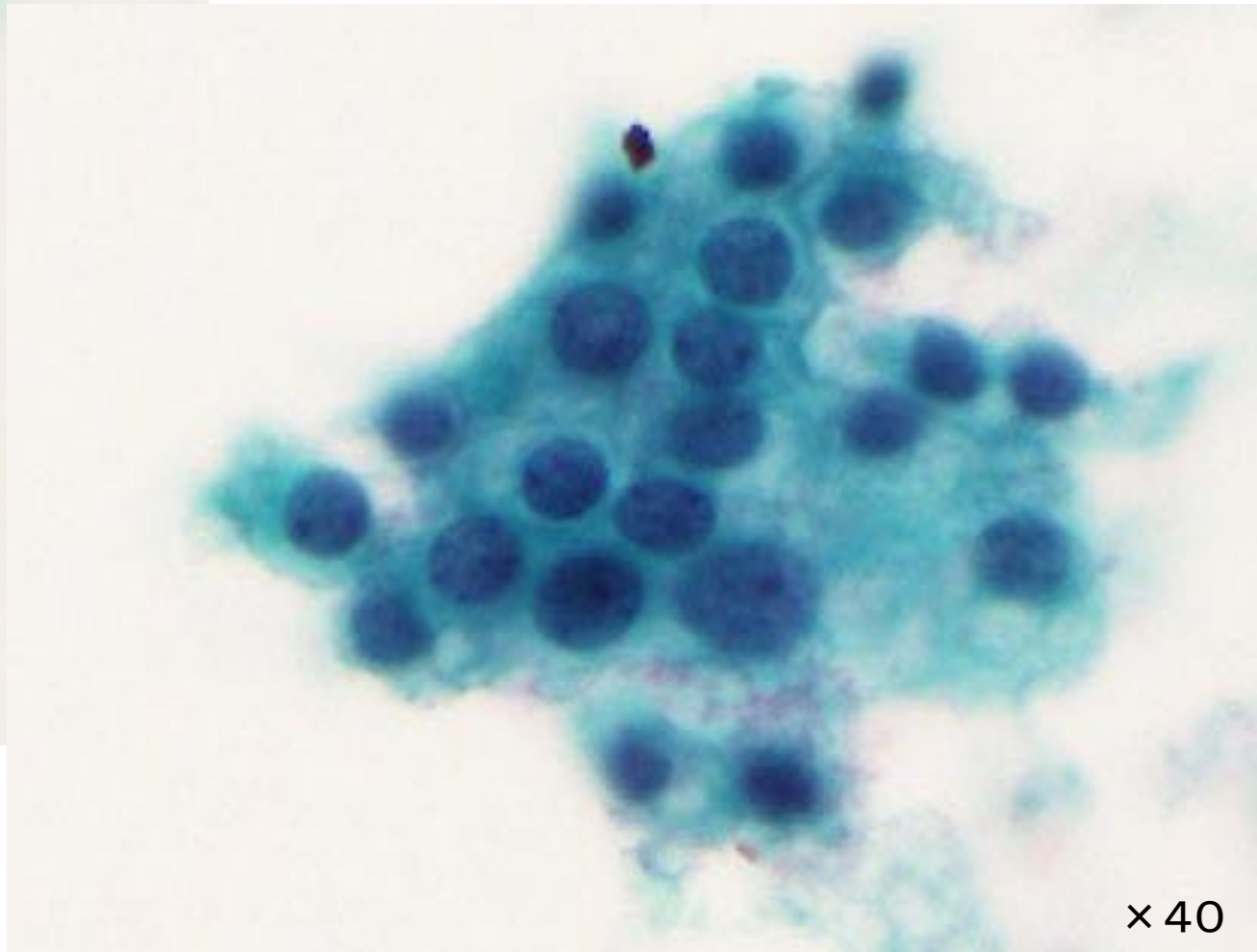
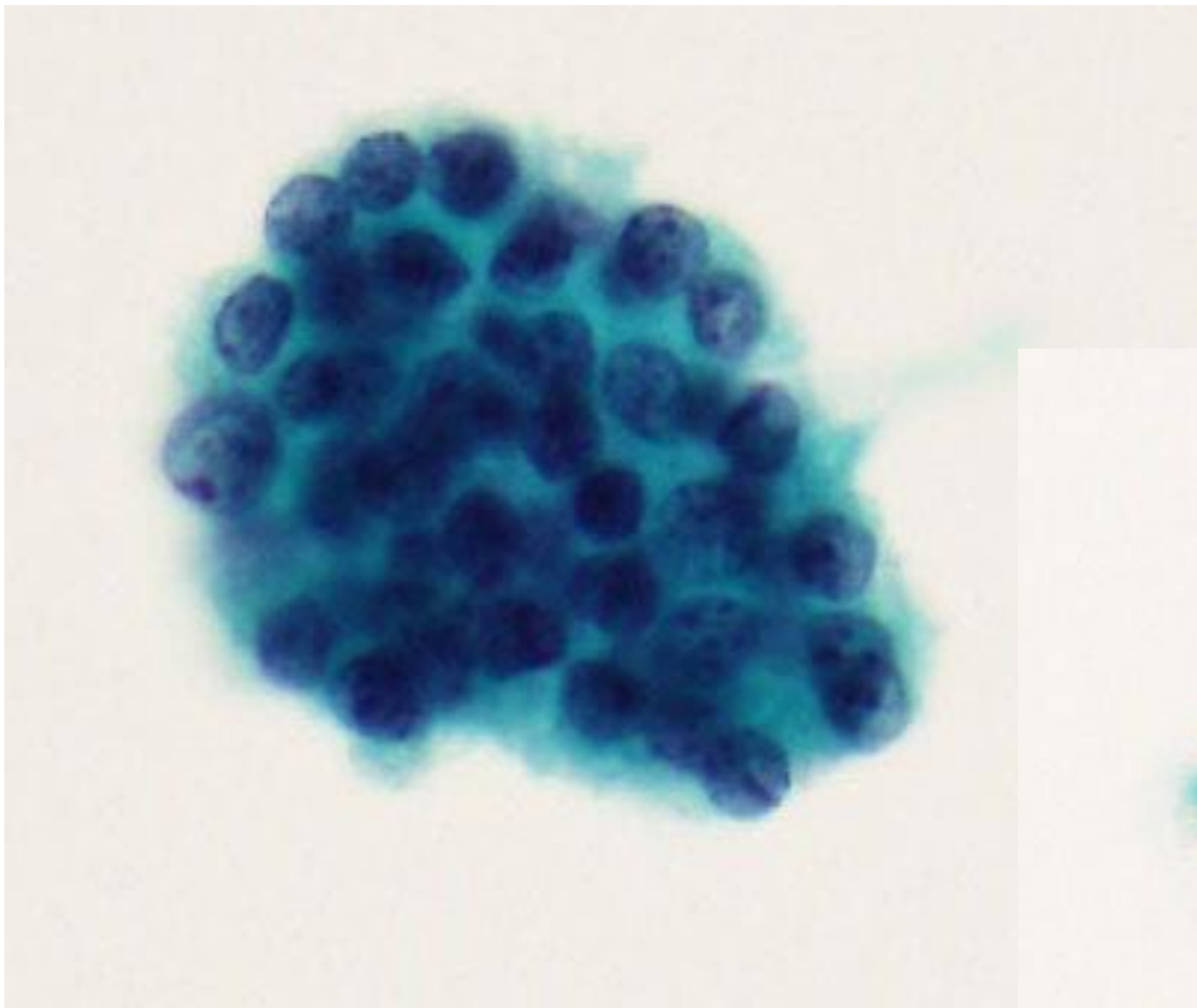
材料：穿刺吸引細胞診(LBC法-Thin prep標本)

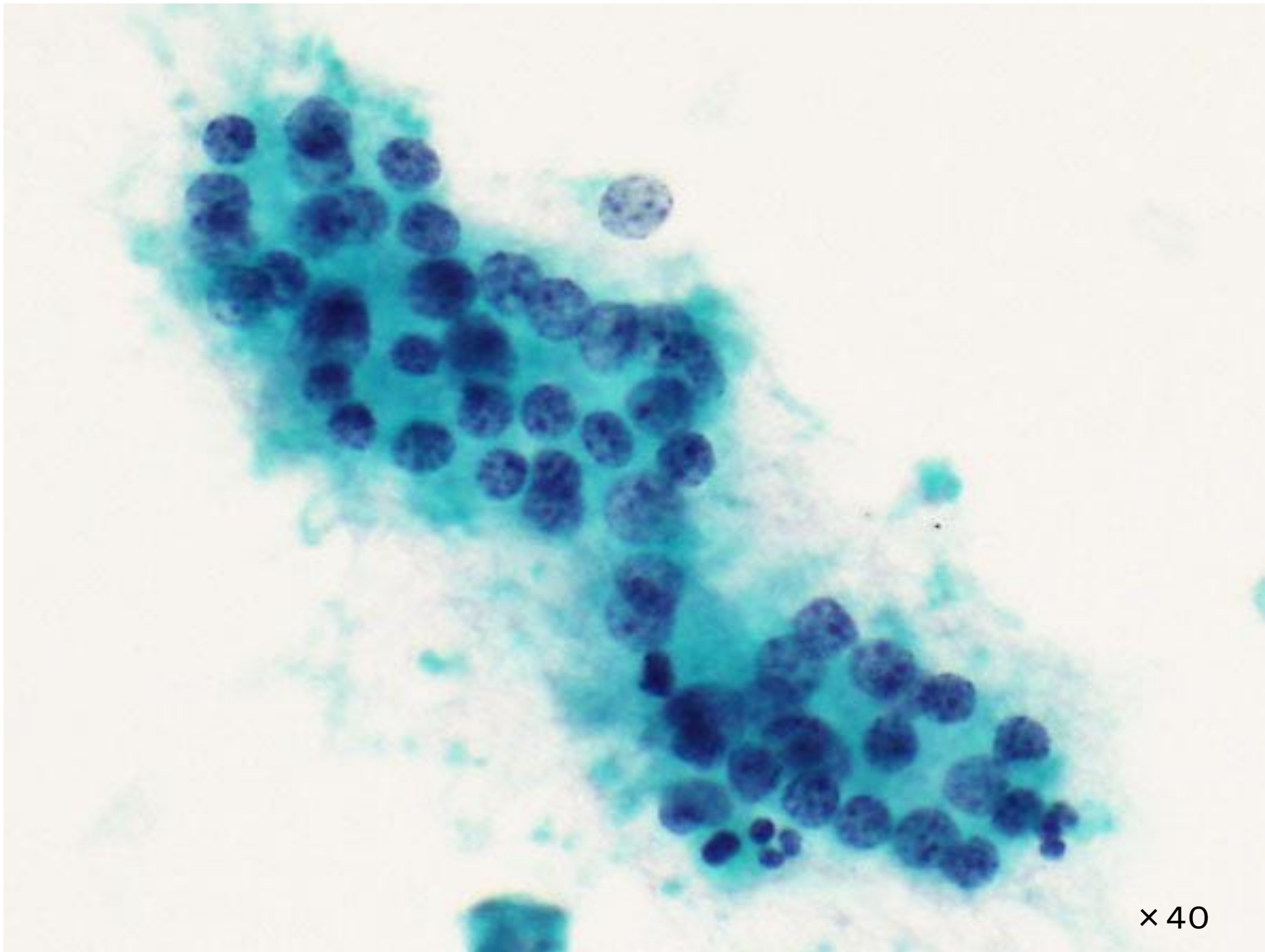


× 20



× 40





× 40